

Measurement and Associations of the Optic Nerve Subarachnoid Space in Normal Tension and Primary Open-Angle Glaucoma



HANRUO LIU, DIYA YANG, TENG MA, WENYUAN SHI, QIANG ZHU, JUN KANG, AND NINGLI WANG

- **PURPOSE:** To measure the area of the optic nerve subarachnoid space (ONSASA) in patients with normal tension glaucoma (NTG), primary open-angle glaucoma (POAG), and controls and examine its association with relevant ocular and systemic parameters.
- **DESIGN:** Cross-sectional study.
- **METHODS:** The study included 40 patients with NTG, 42 with POAG, and 45 healthy controls. B-scan ultrasound was performed binocularly, using a 12.5-MHz linear array probe. The measurement of the optic nerve subarachnoid space (ONSAS) and calculation of the ONSASA using ImageJ 1.51e analysis software was done by 2 experienced observers in a masked manner.
- **RESULTS:** The ONSASA between 3 and 7 mm behind the globe in NTG ($5.15 \pm 0.81 \text{ mm}^2$) was significantly smaller than that in the POAG ($6.24 \pm 1.62 \text{ mm}^2$, $P = .0008$) or control ($6.40 \pm 2.20 \text{ mm}^2$; $P = .0007$) groups. ONSASA in the POAG and control groups were not significantly different ($P = .13$). ONSASA was significantly associated with mean IOP ($P = .0004$) and highest IOP ($P = .0007$). The optic nerve sheath diameter in NTG compared to POAG was significantly different at 3 mm ($4.46 \pm 0.43 \text{ mm}$ vs $4.79 \pm 0.40 \text{ mm}$, $P = .0007$), 5 mm ($4.40 \pm 0.39 \text{ mm}$ vs $4.65 \pm 0.47 \text{ mm}$, $P = .003$), and 7 mm ($4.36 \pm 0.35 \text{ mm}$ vs $4.61 \pm 0.30 \text{ mm}$, $P = .004$) behind the globe.
- **CONCLUSIONS:** The ONSASA is smaller in NTG as compared to normal control. This is compatible with a lower cerebrospinal fluid pressure in the optic nerve in NTG, implying that trans-lamina cribrosa pressure difference might be abnormally higher in the NTG group than in normal controls. (Am J Ophthalmol 2018;186:128–137. © 2017 Elsevier Inc. All rights reserved.)

primary open-angle glaucoma (POAG), other factors are involved in the pathogenesis. They include ocular perfusion pressure, cardiovascular disease, migraine, vasospastic disorders, and low body mass index (BMI).^{2–6} The role of intracranial pressure (ICP) in glaucoma has gained recent interest and it has been suggested that ICP acts as a translaminar counter-pressure to the IOP.⁷ It is postulated that a low cerebrospinal fluid pressure (CSFP) in the subarachnoid space of the retrobulbar optic nerve has an effect on the trans-lamina cribrosa pressure difference (TLCPD) in normal tension glaucoma (NTG).^{8,9} The lack of availability of noninvasive measurement techniques of CSFP, especially in the optic nerve subarachnoid space (ONSAS), makes it difficult to study its role in glaucoma. While CSFP measurement using lumbar puncture is useful in some diseases, it is too invasive to use in clinical studies and does not reflect the CSFP in the ONSAS.¹⁰ A noninvasive method or surrogate for CSFP in the optic nerve would be valuable in studying its role in glaucoma.

An elevation in orbital CSFP leads to an increase in the subarachnoid space around the optic nerve.^{11,12} The neurosurgical literature also reports that raised intracranial pressure causes widening of the ONSAS while intracranial hypotension is associated with a decrease.¹² Wang and associates found that measurements of the mean width of ONSAS (ONSASW) at 3, 9, and 15 mm behind the globe on the magnetic resonance images were smaller in NTG than in control or POAG patient groups.¹³ We felt that measurement of the area of the optic nerve subarachnoid space (ONSASA) could be used as a surrogate for volume of the ONSAS and serve as a more robust indicator of ONSAS than measurement of width at 3 different points. If the CSFP is lower in NTG and the ONSAS is a surrogate for the CSFP, then the ONSASA should be smaller in NTG as compared to POAG and controls. To study this hypothesis we compared the measurements of the area ONSASA in NTG with POAG and healthy controls and studied its associations.

GLAUCOMA IS THE ONE OF THE LEADING CAUSES OF irreversible blindness.¹ While intraocular pressure (IOP) is the only known causal factor for pri-

AJO.com

Supplemental Material available at AJO.com.

Accepted for publication Nov 30, 2017.

From the Beijing Institute of Ophthalmology, Beijing Tongren Hospital, Capital Medical University, Beijing, China.

Inquiries to Ningli Wang, Beijing Tongren Eye Center, Beijing Tongren Hospital, Capital Medical University, Beijing, China 100730; e-mail: wningli@vip.163.com

METHODS

THE MEDICAL ETHICS COMMITTEE OF THE BEIJING TONGREN Hospital approved the study protocol; the randomized,

double-masked, controlled clinical trial was conducted according to the Declaration of Helsinki and all participants signed a written informed consent. The study was registered at <http://www.chictr.org.cn> (Study no ChiCTR-INR-16010398).

The study was conducted in the Beijing Tongren Hospital, Beijing, China between October 2015 and November 2016. Three groups were recruited: 40 patients with NTG, 42 patients with POAG, and 45 healthy control subjects.

The diagnosis of open-angle glaucoma was made based on the presence of glaucomatous abnormalities of the optic nerve head, glaucomatous visual field defects, and an open angle on gonioscopy. IOP was not required to make a diagnosis but was used to distinguish NTG from POAG. All glaucoma patients were admitted to have the IOP measured at 2 AM, 6 AM, 8 AM, 10 AM, 2 PM, 6 PM, and 10 PM using a Goldmann applanation tonometer. In the NTG group, all untreated IOP measurements were ≤ 21 mm Hg. Those in the POAG group were required to have at least 2 IOP measurements > 21 mm Hg. NTG and POAG were enrolled from the glaucoma clinic at the Beijing Tongren Eye Center.

All glaucoma patients underwent a complete ophthalmic examination including best-corrected visual acuity, refraction, slit-lamp biomicroscopy, applanation tonometry, gonioscopy using anterior segment optical coherence tomography (Casia ss-1000; Tomey Corporation, Nagoya, Japan), measurement of central corneal thickness, dilated optic disc and fundus examination, photography of the optic nerve head and fundus (fundus camera EOS D60; Canon Co, Utsunomiya, Tochigiken, Japan), automated perimetry (central 30-2 full-threshold program; Humphrey Field Analyzer; Zeiss Meditec AG, Jena, Germany), and spectral-domain optical coherence tomography (Spectralis; Heidelberg Engineering GmbH, Heidelberg, Germany). Two glaucoma specialists (N.W. and H.W.) examined the optic disc photographs independently and in a masked manner. Both specialists adjudicated disagreements and any patient in whom they disagreed about the diagnosis were excluded. The NTG patients had never used antiglaucomatous medication or had stopped taking any antiglaucomatous medication at least 6 weeks before inclusion into the study. In POAG patients the IOP was controlled within the normal range at the time of ultrasound examination.

The control group included healthy subjects who were recruited from the local community by advertisement and matched for age with the study group. They underwent the same examination as the glaucoma patients. Two glaucoma specialists examined the optic disc and fundus to confirm the absence of any evidence of glaucoma or other ocular disease. Those with refractive error of ≥ 8 diopters were excluded, as were those with a family history of glaucoma and an IOP > 21 mm Hg.

Exclusion criteria for all participants were a myopic refractive error of more than 8 diopters and a history or

findings of any ocular diseases other than glaucoma that could affect the IOP or visual field. Those with neurologic disorders that could influence intracranial pressure or a history of any cranial surgery or traumatic brain injury, those using drugs such as carbonic anhydrase inhibitors, and those who had undergone a lumbar puncture previously at any time were also excluded.

Other parameters collected included age, sex, weight, height, BMI, waistline, and head circumference. Systolic (SBP) and diastolic blood pressure (DBP) were measured using a standardized mercury sphygmomanometer at least 5 minutes after the participant assumed a sitting position. Mean arterial blood pressure (MABP) was calculated as $1/3 \times$ systolic blood pressure $+ 2/3 \times$ diastolic blood pressure.

The right eye of each participant was included in the analysis. A single investigator (T.M.) experienced in the use of transorbital ultrasonography and masked to the diagnosis acquired ultrasound images from both eyes of all participants using a 12.5-MHz linear array probe (L15-7io; Philips, Bothell, Washington, USA). The patient lay on the examination couch in a supine position. A clear barrier covered the lid of the eye being examined while the fellow eye focused on a fixation target. Following application of coupling gel, the transducer was placed over the upper eyelid in an axial plane. This sonographic section provides a transverse view of the globe and the structures in the retrobulbar area (Figure 1). The image was stored for later off-line analysis. Two experienced observers (Y.C. and J.D.) evaluated the images in a masked manner.

The stored ultrasound photographs were used to measure the axial length. The optic nerve diameter (OND) and optic nerve sheath diameter (ONSD) were measured 1, 3, 5, and 7 mm from the optic nerve head, as illustrated in Figure 1 (Bottom right). From these measurements the ONSASW (width of both sides of the ONSAS) at these specific locations was calculated as ONSD minus OND. To establish ONSASA, ImageJ 1.51e analysis software (available in the public domain at <http://rsbweb.nih.gov/ij/>) was used.¹⁴ With this software, the entire ONSAS between 3 and 7 mm can be outlined and thus using this software permits an area to be measured. If desired, an average width can be calculated as the determined ONSASA/axial length of the captured region, which in this case is 4 mm. In all cases, images were captured when the ONSAS width was maximal. For each photographic image, measurements were calibrated using the scale at the base of the image included in the ultrasound system. The ONSASA outline was defined from the photographic image using the "Freehand selections" tool in ImageJ. Following tracing, the ImageJ software calculated the ONSASA area. Inter- and intraobserver reliability was calculated. In order to assess intraobserver reliability, all measurements on all images were repeated after 1 month.

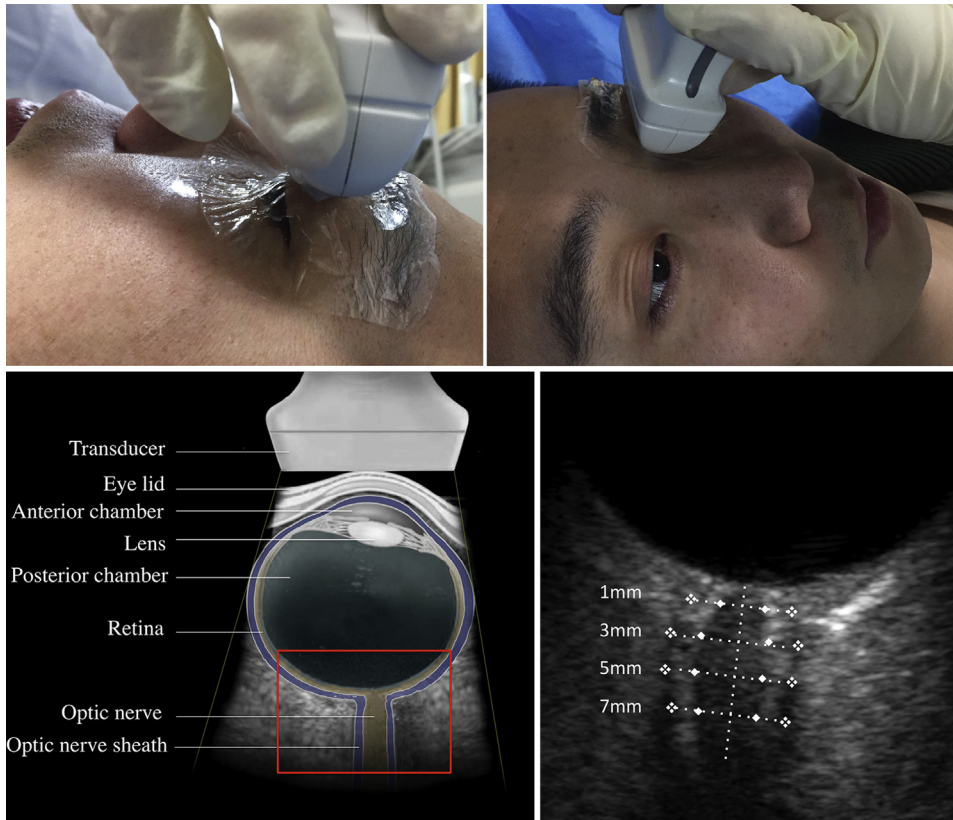


FIGURE 1. Examples of ultrasound scan of the retrobulbar optic nerve. (Top left) A clear barrier was placed over the patient's eyelid, followed by application of ultrasound gel. (Top right) The fellow eye focused on a distant point. (Bottom left) A sonographic section provides the transverse view of the globe and the structures in the retrobulbar area and the optic nerve complex is seen as a sharply defined hypoechoic stripe in the echogenic retrobulbar fat. (Bottom right) The optic nerve sheath was measured at a depth of 1, 3, 5, and 7 mm behind the orbit in the zoom mode.

All statistical testing was performed using SPSS (SPSS for Mac, v. 24.0; IBM-SPSS, Chicago, Illinois, USA). Data are presented as mean values \pm standard deviation. The Shapiro-Wilk *W* test was used to check for normal distribution of data and the Levene test was used to examine homogeneity of the variance. The diastolic and systolic blood pressure, refractive error, and sex were not normally distributed, while weight and BMI did not show homogeneity of variance. The Kruskal-Wallis test with post hoc Dunn multiple comparisons was used to compare these parameters between the 3 diagnostic groups which the variables not conforming to the normal distribution. One-way analysis of variance with post hoc least significant difference analysis was performed to assess significant differences between groups with the variables conforming to the normal distribution. A *t* test for unpaired samples analysis was performed to compare the mean deviation between the NTG and POAG groups. ONSD, OND and ONSASW were analyzed using Two-way repeated-measures ANOVA with 3 groups as the between-subjects factor and the different location as within-subjects factor. Spearman correlation was used to study associations be-

tween variables. Significance tests were two-sided and $P < 0.05$ was considered statistically significant. A linear regression analysis was performed to assess the association between ONSASA and mean IOP in NTG group. Intra-class correlation coefficient (ICC) was used to determine the inter- and intraobserver reliability.

RESULTS

TABLE 1 SUMMARIZES THE DEMOGRAPHICS OF THE 3 groups. There was no statistically significant difference in age, sex, height, weight, BMI, blood pressure (systolic, diastolic, and mean), waistline, or head circumference between the groups. The mean and highest IOP were significantly lower (both $P < .001$) in the NTG and control groups than in the POAG group (**Table 2**). The NTG and the POAG groups had a similar mean defect ($P = .61$). Best-corrected visual acuity was better, mean refractive error higher, and retinal nerve fiber layer thicker in the control group as compared to the NTG and POAG groups

TABLE 1. Demographics and Systemic Measurements in the Study Population

	Healthy	NTG	POAG	P Value ^a
Number	45	40	42	
Age	48.2 ± 9.0	50.5 ± 12.3	51.7 ± 10.9	.53
Sex (male/female)	22/23	19/21	20/22	.60
Weight (kg)	69.2 ± 9.9	67.9 ± 12.2	68.5 ± 13.0	.57
Height (cm)	168.9 ± 8.1	169.1 ± 7.5	166.7 ± 10.9	.35
BMI (kg/m ²)	23.7 ± 2.9	22.9 ± 2.5	24.8 ± 2.1	.69
Waist (cm)	81.5 ± 8.9	80.9 ± 7.5	85.3 ± 9.0	.34
Head circumference (cm)	54.2 ± 4.1	55.9 ± 3.7	53.8 ± 4.9	.30
Arterial blood pressure (mm Hg)				
Systolic: median quartiles	120 (113,129)	120 (115,130)	120 (117,134)	.45
Diastolic: median quartiles	80 (71, 85)	80 (72, 86)	80 (75, 89)	.17
Mean arterial pressure	94.8 ± 8.2	91.9 ± 7.7	94.1 ± 5.9	.18

BMI = body mass index; NTG = normal tension glaucoma; POAG = primary open-angle glaucoma.

^aStatistical significance of difference between the control group and the 2 glaucoma groups.

TABLE 2. Measurements (Mean ± Standard Deviation) of Ocular Parameters in the Study Population

	Healthy	NTG	POAG	P Value ^a
Number	45	40	42	
Central corneal thickness (μm)	537 ± 35	529 ± 30	532 ± 39	.75
Refractive error (D) median (quartiles)	-0.50 (-2.50, 0.00)	-3.50 (-4.50, 0.00)	-3.50 (-5.50, 0.00)	.03
Mean IOP (mm Hg)	13.8 ± 2.7	13.2 ± 2.1	24.8 ± 3.9 ^b	<.001
Highest recorded IOP (mm Hg)	16.0 ± 2.1	15.7 ± 2.0	32.3 ± 7.8 ^b	<.001
Mean defect (dB)	-	-14.3 ± 7.8	-16.8 ± 12.1	.31
Axial length (mm)	23.1 ± 1.5	23.6 ± 2.1	23.9 ± 2.0	.65
RNFL thickness (μm)	114 ± 15	81 ± 21	79 ± 18	<.001
BCVA (logMAR)	0.00 ± 0.00	0.61 ± 0.12	0.70 ± 0.18	<.001
Median ocular perfusion pressure [(2/3 diastolic BP + 1/3 systolic BP)]	95.8 ± 11.3	97.2 ± 15.6	96.8 ± 13.7	.17

BCVA = best-corrected visual acuity; BP = blood pressure; D = diopters; IOP = intraocular pressure; NTG = normal tension glaucoma; POAG = primary open-angle glaucoma.

^aStatistical significance of difference between the control group and the 2 glaucoma groups.

^bSignificantly higher than the other 2 groups.

($P < .001$; $P = .03$; $P < .001$), whereas no significant difference was found between the NTG and POAG groups ($P = .62$; $P = .71$; $P = .75$). There was no difference in refractive error between the 2 glaucoma groups ($P = .82$). Central corneal thickness, axial length, and median ocular perfusion pressure was similar in all 3 groups ($P = .75$).

The measurements of the optic nerve are shown in Table 3. Intra- and interobserver agreement of measurements were excellent (Table 4). In all groups the OND was significantly smaller with increasing distance from the globe ($P < .05$). There was no significant difference in OND measured at 1 mm behind the globe between the control group and the 2 glaucoma groups ($P = .74$). The OND measured at 3, 5, and 7 mm behind the globe was

similar in NTG and POAG ($P = .62$, $P = .18$, and $P = .27$, respectively) but significantly smaller than in controls ($P = .05$, $P = .04$, and $P < .001$, respectively) (Table 3). The ONSD at 1 mm was similar in all 3 groups ($P = .24$). At 3, 5, and 7 mm behind the globe the ONSD was significantly smaller in NTG than in POAG ($P = .001$, $P = .003$, and $P = .004$, respectively); measurements in both glaucoma groups were smaller than in the controls ($P < .001$). The measurement of ONSASW at 1 mm was similar in all groups ($P = .52$). ONSASW at 3, 5, and 7 mm in NTG was less than in POAG ($P = .001$, $P < .001$, and $P = .002$, respectively) and controls ($P < .001$, $P = .001$, and $P = .002$, respectively); there was no difference between POAG and controls ($P = .32$,

TABLE 3. Measurements of Optic Nerve Diameter, Optic Nerve Sheath Diameter, and Area of the Optic Nerve Subarachnoid Space (Mean ± Standard Deviation) in Normal Tension Glaucoma, Primary Open-Angle Glaucoma, and Healthy Controls

	Healthy	NTG	POAG	P Value
OND at 1 mm behind globe (mm)	3.19 ± 0.44	3.10 ± 0.28	3.09 ± 0.15	.67 ^a
OND at 3 mm behind globe (mm)	3.28 ± 0.37	3.01 ± 0.15	3.02 ± 0.09	.059 ^a
OND at 5 mm behind globe (mm)	3.25 ± 0.34	2.87 ± 0.29	2.90 ± 0.23	.049 ^a
OND at 7 mm behind globe (mm)	3.25 ± 0.06	2.78 ± 0.35	2.82 ± 0.32	<.001 ^a
Average	3.24 ± 0.29	2.94 ± 0.35	2.96 ± 0.29	.002 ^a
P value	.043 ^b	.019 ^b	.031 ^b	.001 ^c
ONSD at 1 mm behind globe (mm)	4.79 ± 0.47	4.71 ± 0.41	4.68 ± 0.34	.247 ^a
ONSD at 3 mm behind globe (mm)	5.05 ± 0.27	4.46 ± 0.43	4.79 ± 0.40	<.001 ^a
ONSD at 5 mm behind globe (mm)	5.03 ± 0.35	4.40 ± 0.39	4.65 ± 0.47	<.001 ^a
ONSD at 7 mm behind globe (mm)	5.08 ± 0.49	4.36 ± 0.35	4.61 ± 0.30	<.001 ^a
Average	4.99 ± 0.39	4.48 ± 0.37	4.48 ± 0.37	.001 ^a
P value	.036 ^b	.042 ^b	.039 ^b	<.001
ONSASW at 1 mm behind globe (mm)	1.60 ± 0.23	1.61 ± 0.20	1.59 ± 0.19	.523 ^a
ONSASW at 3 mm behind globe (mm)	1.77 ± 0.14	1.45 ± 0.18	1.77 ± 0.32	<.001 ^a
ONSASW at 5 mm behind globe (mm)	1.78 ± 0.18	1.53 ± 0.30	1.79 ± 0.24	<.001 ^a
ONSASW at 7 mm behind globe (mm)	1.73 ± 0.20	1.58 ± 0.27	1.79 ± 0.21	<.001 ^a
Average	1.72 ± 0.19	1.54 ± 0.24	1.74 ± 0.20	<.001 ^a
P value	.047 ^b	.027 ^b	.043 ^b	.002 ^c
ONSASA from 3 mm to 7 mm behind globe (mm ²)	6.40 ± 2.20	5.15 ± 0.81	6.24 ± 1.62	<.001 ^a

NTG = normal tension glaucoma; OND = optic nerve diameter; ONSASW = width of both sides of the ONSAS (ONSD – OND); ONSASA = area of the optic nerve subarachnoid space; ONSD = optic nerve sheath diameter; POAG = primary open-angle glaucoma.

^aStatistical significance of the difference between the control group, POAG group, and NTG group at the same location (analysis of variance).

^bStatistical significance of the difference between the positions at 1, 3, 5, and 7 mm within the same group (analysis of variance).

^cStatistical significance of the crossover effect among 3 study groups and 4 measurement positions (analysis of variance).

$P = .44$, and $P = .51$, respectively). The ONSASA between 3 and 7 mm in NTG was less than in POAG ($P < .001$). There was no significant difference in the ONSASA between POAG and controls ($P = .05$) (Figure 2 and Table 3).

The associations of ONSASA are shown in Table 5. There was a positive correlation between ONSASA and mean IOP ($r = 0.66$, $R^2 = 0.40$, $P = .0004$), as well as highest recorded IOP ($r = 0.48$, $R^2 = 0.44$, $P = .0007$), in the NTG group (Figure 3). ONSASA was not associated with age, central cornea thickness, axial length, refractive error, RNFL thickness, or best-corrected visual acuity in any of the groups. Mean defect was also not significantly associated with ONSASA in either of the glaucoma groups (Table 5).

A multivariate analysis was performed in which the optic nerve subarachnoid space was the dependent variable and the study group type, the optic nerve diameter, and the amount of glaucomatous visual field loss were independent variables. It showed that the ONSASA measured from 3 to 7 mm behind the globe was associated with the normal pressure group ($P < .001$; standardized coefficient beta = -0.50 ; nonstandardized regression coefficient beta = -0.23 ; 95% confidence interval [CI], -0.14

to -0.03), whereas the amount of visual field defect ($P = .71$) and the mean optic nerve diameter ($P = .86$) were not associated with the space area.

DISCUSSION

THIS STUDY WAS CONDUCTED TO EVALUATE WHETHER measurement of optic nerve subarachnoid space in glaucoma patients is an appropriate indirect tool to predict ICP, and to determine how this correlates with clinical observations in these patients. Our data demonstrated that NTG patients had a significantly smaller subarachnoid space compared with POAG patients. Ultrasound-based assessment of the ONSD is a validated method for indirect measurement of the CSFP.^{15,16} In these studies, the ONSD was measured at 3 mm behind the globe. It should, however, be noted that the major limiting factor of this technique is that the diameter of the optic nerve can in some cases influence the ONSD. For example, patients with optic atrophy present a reduced optic nerve diameter, but the sheath diameter is comparable to healthy individuals.¹⁷

TABLE 4. Interobserver and Intraobserver Reproducibility of Optic Nerve Diameter, Optic Nerve Sheath Diameter, and Area of the Optic Nerve Subarachnoid Space Measurements

Measurement	Interobserver		Intraobserver	
	Difference (95% LoA) (mm)	ICC (95% LoA)	Difference (95% LoA) (mm)	ICC (95% LoA)
OND at 1 mm behind globe	0.09 (−0.26 to 0.43)	0.91 (0.88–0.94)	0.05 (−0.27 to 0.35)	0.91 (0.88–0.94)
OND at 3 mm behind globe	0.05 (−0.26 to 0.35)	0.91 (0.89–0.93)	0.04 (−0.25 to 0.34)	0.92 (0.88–0.94)
OND at 5 mm behind globe	0.04 (−0.24 to 0.34)	0.89 (0.85–0.92)	0.05 (−0.28 to 0.35)	0.90 (0.90–0.92)
OND at 7 mm behind globe	0.05 (−0.36 to 0.25)	0.91 (0.86–0.94)	0.05 (−0.24 to 0.34)	0.91 (0.86–0.93)
ONSD at 1 mm behind globe	−0.08 (−0.54 to 0.38)	0.90 (0.85–0.92)	0.06 (−0.23 to 0.35)	0.91 (0.87–0.94)
ONSD at 3 mm behind globe	−0.10 (−0.44 to 0.25)	0.91 (0.84–0.94)	0.04 (−0.27 to 0.34)	0.92 (0.88–0.94)
ONSD at 5 mm behind globe	−0.11 (−0.43 to 0.24)	0.90 (0.83–0.90)	0.05 (−0.27 to 0.39)	0.90 (0.83–0.92)
ONSD at 7 mm behind globe	−0.16 (−0.54 to 0.24)	0.91 (0.89–0.95)	0.04 (−0.24 to 0.36)	0.92 (0.88–0.95)
ONSASA from 3 mm to 7 mm behind globe	0.06 (−0.26 to 0.33)	0.92 (0.85–0.94)	0.05 (−0.25 to 0.32)	0.93 (0.90–0.97)

ICC = intraclass correlation coefficient; LoA = limits of agreement.

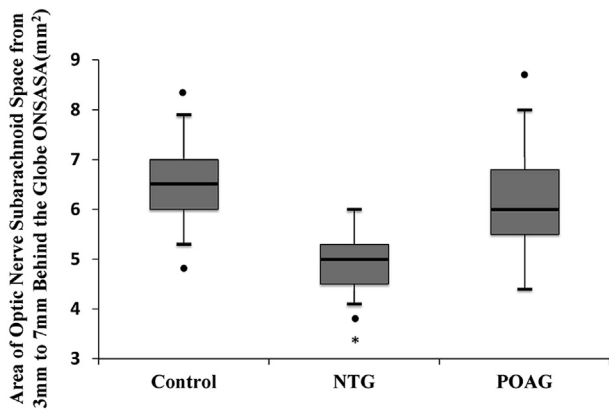


FIGURE 2. Box plots showing the differences in the area of the optic nerve subarachnoid space (ONSASA) measured from 3 mm to 7 mm behind the globe in patients with normal tension glaucoma (NTG), patients with primary open-angle glaucoma (POAG), and controls. Asterisk (*) indicates a significant difference between groups ($P \leq .05$; ANOVA with post hoc analysis).

The thickness of the dura of the ONS is 0.35–0.5 mm, with its thickest section close to the sclera. This distribution pattern may explain why there were no differences observed between any groups at the 1 mm measurement point.¹⁸ At the 9 mm measurement point behind the globe and beyond, in the majority of cases, the optic nerve sheath edges were hard to identify (data not shown). The optic nerve is located in the intraconal portion of the orbit, which is confined by the extraocular muscles. Given this location, the intraconal pressure might influence the optic nerve subarachnoid space. The ONSD is calculated perpendicular to the vertical axis of the scanning plane 3–7 mm behind the globe. At this point, the optic nerve sheath structure may be more prone to expansion.

TABLE 5. Associations of Optic Nerve Sheath Subarachnoid Space Area Measured Between 3 mm and 7 mm Behind the Globe in Normal Tension Glaucoma Patients, Primary Open-Angle Glaucoma Patients, and Healthy Controls

	Healthy (N = 45)		NTG (N = 40)		POAG (N = 42)	
	P	r	P	r	P	r
Age	.50	−0.20	.81	0.12	.77	−0.002
Central cornea thickness	.71	0.01	.92	0.23	.39	−0.003
Refractive error	.38	−0.08	.54	−0.07	.60	−0.005
Mean IOP	.56	−0.27	.0004	0.66	.78	−0.03
Highest recorded IOP	.61	−0.04	.0007	0.48	.82	−0.14
Mean defect	-	-	.09	0.29	.13	−0.38
Axial length	.25	0.34	.49	0.12	.47	−0.03
RNFL thickness	.47	−0.076	.17	−0.05	.37	−0.017
BCVA	.23	−0.019	.71	0.02	.42	0.009

BCVA = best-corrected visual acuity; IOP = intraocular pressure; NTG = normal tension glaucoma; POAG = primary open-angle glaucoma.

Spearman correlations are depicted (values on coefficient of correlation [r] and P values [P]).

Expansion owing to ICP would lead to an increase in sheath thickness in that retrobulbar segment of the optic nerve. With this in mind, it would appear that measurement of the optic nerve sheath 3–7 mm behind the globe is optimal to predict a change of ICP.

Our finding relating to the optimal measurement site is supported by reported investigations, which employed cadaveric optic nerves as an experimental model.¹⁹ The findings from these earlier studies suggested that the mean diameter increased by 60% at 3 mm behind the optic nerve head, but only by 35% at 10 mm distance after

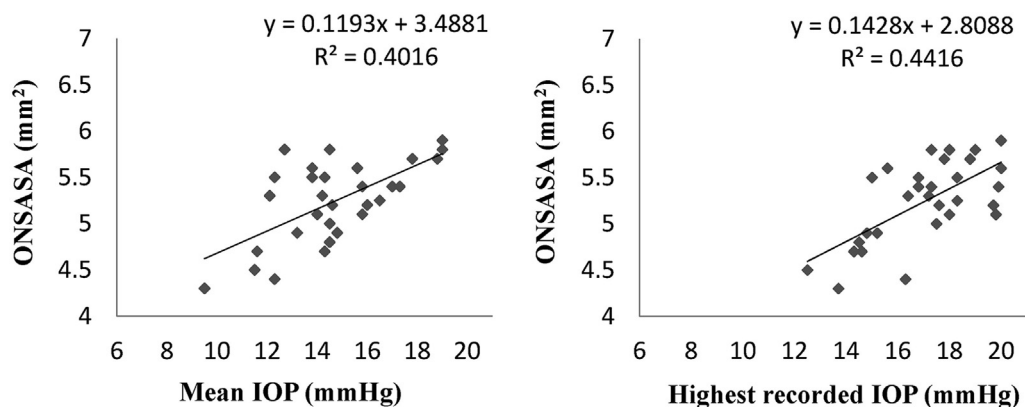


FIGURE 3. Scatterplot showing the relationship between the mean intraocular pressure (IOP) and the area of the optic nerve subarachnoid space (ONSASA) in the normal tension glaucoma group.

gelatin-induced widening of the subarachnoid space. In addition, studies using sonography to measure ONSD have commonly used a site 3 mm behind the globe as a reference point to make correlations with ICP.^{20,21} As ultrasound technology advances, higher-resolution images of the optic nerve subarachnoid space can be generated. The use of a 12.5-MHz probe in the present study has enabled more detailed measurements of both optic nerve sheath diameter and optic nerve diameter. This advance affords greater reliability in image capture and measurements with the subarachnoid space and consequently increased power to predict ICP, which will overcome differences that may occur owing to individual anatomy and pathologic influence. A number of factors, however, still need to be considered that could influence our findings. For example, a change of ICP can give rise to a change of shear stress over the optic nerve sheath wall, which could cause an irregular deformation of the ONSAS volume. There are several other factors that also need to be taken into account, such as the nonlinear nature of optic nerve sheath stiffness, altered CSF distribution, an abnormal response to external stimuli, and/or even a different retrobulbar remodeling in NTG patients.²² To reduce the influence of deformation in predicting ICP, it may be prudent to obtain measurements at multiple points rather than a single site, which will create a more robust anatomic picture and reduce anomalies. In this study we employed ONSASA acting as a surrogate for volume of the optic nerve subarachnoid space. ONSASA is the cross-sectional 2-dimensional area of a single ultrasonographic slice calculated between 3 mm and 7 mm positions posterior to the globe. This approach goes some way to counter errors arising from deformation and thus provides a more reflective assessment of ONSAS changes under different clinical scenarios. It is possible to derive an estimated ONSAS volume from the ONSASA data, but this would always correlate and would not account for asymmetric deformations. To further enhance predictive power, images would need

to be captured in multiple planes, which could also permit 3-dimensional modeling to take place and, ultimately, a more accurate prediction of volume. Nevertheless, the current approach is an advance on current methods and ONSASA serves as a useful proxy for ONSAS volume changes.

In the current study, a narrow ONSASW in NTG groups was observed (Figure 4). The results of our study agree with previous experimental and clinical findings that suggested normal-pressure glaucoma was associated with an abnormally low CSFP.^{9,23–25} These observations are also in agreement with data reported in other ONSD-related studies.¹³ Furthermore, a previous study established a good correlation between ultrasound and magnetic resonance imaging of the ONS.²⁶ However, there have been other ONSD-related studies using computed tomography scan²⁷ and ultrasound²⁸ that reported different results. Jaggi and associates²⁷ found that NTG patients had a higher ONSD than control subjects, while Abegao Pinto and associates²⁸ suggested that the ONSD does not differ between these groups. It is important to consider the difference in observed outcomes of these reported studies and the current work; the basis of this could arise for a number of reasons.

The current study employed a greater number of subjects than the study by Jaggi and associates,²⁷ which would reduce the effect of individual variation and allow greater statistical power. It is also important to consider the position of the head during image capture; in the current study patients were in a supine position, whereas Jaggi and associates²⁷ imaged individuals in a prone position. A prone position has been demonstrated to influence CSF distribution in the central nervous system and allows the effects of gravity to be considered. In addition, the current study established measurements at defined distances behind the globe, whereas Jaggi and associates²⁷ measured the point giving the greatest optic nerve sheath diameter within the orbit for each patient.

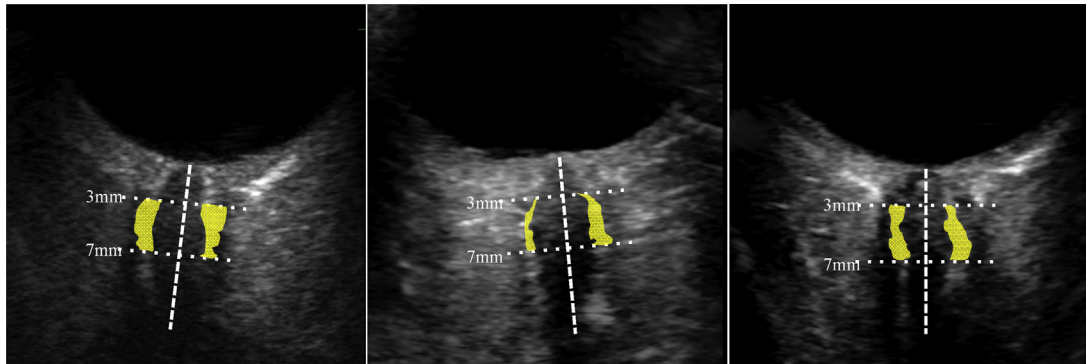


FIGURE 4. Representative images of the area of optic nerve subarachnoid space sonography of healthy (Left), normal tension glaucoma (Middle), and primary-open angle glaucoma subjects (Right).

With regard to the study by Abegao Pinto and associates,²⁸ the refractive status of the patients could have introduced bias, as the properties of the sclera are different from hyperopic to myopic patients. Because they employed a 7.5-MHz B-scan ultrasound probe (Antares ecograph device; Siemens, Munich, Germany), the resolution of the sonographic images is lower than the 12.5-MHz probe used in our study. This in turn is likely to impact on the accuracy of measurements taken for the optic nerve sheath diameter. The occurrence of artifacts may also have affected ONSD measurement. The transbulbar sound direction and the incidence of the ultrasound beam on the lamina cribrosa²⁹ or the dura mater may produce acoustic shadows behind the globe. The incidence of these artifacts grows greater if the probe has a frequency of <7.5 MHz. The current study employed a 12.5-MHz ultrasound probe, which can reduce artifacts and generate more reliable images and acquire accurate measurements of both optic nerve sheath diameter and optic nerve diameter.

ONSASA is defined as the cross-sectional 2-dimensional area of optic nerve subarachnoid space at its widest point determined between 3 and 7 mm posterior to the optic nerve head. Therefore, a difference in optic nerve diameter between the study groups may have influenced the calculations of the optic nerve subarachnoid space, in particular, because a glaucomatous loss of optic nerve fibers or an atrophic nerve leads to a decrease. As shown in Table 3, both the NTG group and POAG group had significantly smaller optic nerve diameters at 3, 5, and 7 mm behind the globe than the control group. Correspondingly, both glaucomatous groups had significantly smaller optic nerve sheath diameters than the healthy group at 3, 5, and 7 mm behind the globe. These findings could be explained by the sheath ultrastructure and optic nerve subarachnoid space anatomic structures. Optic nerve sheath consists of surprisingly flexible dural tissue and radially oriented trabecular fibers that traverse the subarachnoid space and connect the pia mater of the nerve with the innermost arachnoid layer of the sheath.^{30,31} Both

trabecular fibers and sheath collagen structure may help to maintain the stability of the space structure. In addition, there was no significant difference in optic nerve diameter in both glaucoma groups, and there was no significant difference in the amount of glaucomatous mean defect and RNFL thickness in both groups (Tables 2 and 3). Glaucoma-associated differences in the optic nerve diameter as a component for the calculation of the subarachnoid space could thus be excluded. Moreover, a multivariate analysis adjusting the ONSASA for optic nerve diameter and visual field defect showed that the decreased ONSASA was associated with the NTG group independent of the severity of the visual field defect.

Interestingly, there was a positive correlation between ONSASA measurement and mean IOP in NTG patients; however, no such correlation was observed in the healthy control or POAG groups. Abegao Pinto and associates²⁸ have previously reported similar outcomes. A possible explanation is that IOP measured by Goldmann applanation tonometry could not affect the forces acting in the retro-lamina cribrosa space, while the forces may affect IOP, which could be linked to aqueous humor drainage. ICP may influence aqueous humor drainage by modulating ocular venous drainage.³² Intracranial blood volumes vary reciprocally with changes in the CSF volume, so a change in CSF volume could influence the intracranial venous sinus flow and influence the drainage of the superior ophthalmic veins. The superior ophthalmic veins are responsible for the anterior ciliary vein drainage, which are associated with aqueous humor drainage.³³ Therefore changes in ICP could possibly impact on IOP. Thus, any unknown structural weaknesses or changes along the extraocular drainage pathway in NTG patients would weaken the buffer capacity and lead to a similar change in aqueous humor drainage. There is evidence that the diameter and rigidity of peripapillary vessels are different in NTG patients, and it is also recognized that they display a decrease in prevalence of spontaneous venous phenomenon. The underlying mechanism and the degree of the impact of

this vascular venous dysregulation on IOP will be a topic for further investigation. Hypothetically, if there is a greater upstream obstruction in the trabecular meshwork or other components of the drainage pathway in POAG patients, this could interfere with the superior ophthalmic vein drainage, which might explain why this ONSD would not have correlated with IOP.

There are several potential limitations to our study. First, the number of patients in the study was relatively small. Nevertheless, the difference between the study groups reached the level of statistical significance. More comprehensive studies drawing on larger cohorts for each group are still needed to further evaluate the correlation between NTG and ONSAS. Secondly, as a full neurologic examination was not performed in the control group, there is the possibility of a contamination of the experimental groups by individuals with a yet undiagnosed neurologic clinical

condition. Although the control subjects were not known to have either optic nerve or intracranial disease, none had undergone a complete assessment.

In summary, the narrower optic nerve subarachnoid space in patients with open-angle glaucoma with normal pressure compared with those with high pressure suggests a lower orbital CSFP in normal-pressure glaucoma. Orbital imaging techniques, such as noninvasive ultrasound-based ONSD assessment, may provide further insights into the forces acting behind the lamina cribrosa. More studies will be needed to further investigate the intriguing relationship between ICP and the optic nerve, whose significance may be of particular importance in NTG patients and have pathologic and clinical importance, implying that the trans-lamina cribrosa pressure difference might be abnormally higher in the NTG group than in normal controls.

FUNDING/SUPPORT: THIS STUDY WAS SUPPORTED BY THE PRIMING SCIENTIFIC RESEARCH FOUNDATION FOR THE JUNIOR researcher in Beijing Tongren Hospital, Capital Medical University (2016-YJJ-ZZL-021), the National Natural Science Fund Projects of China (81271005), and the National Natural Science Fund Projects of China (81300767). Financial Disclosures: The following authors have no financial disclosures: Hanruo Liu, Diya Yang, Teng Ma, Wenyuan Shi, Zhu Qiang, Jun Kang, and Ningli Wang. All authors attest that they meet the current ICMJE criteria for authorship.

Other Acknowledgments: The authors thank Dr M. Wormstone (School of Biological Sciences, Norwich Research Park, University of East Anglia, Norwich, UK) and Dr H. Killer (Department of Ophthalmology, Cantonal Hospital, Aarau, Switzerland) for providing professional advice, Dr H. Wang for help assessing the fundus photographs and optic disc photographs, and Drs Y. Chen and J. Du for help assessing the ultrasound images. (Drs H. Wang, Y. Chen, and J. Du are all affiliated with Beijing Tongren Eye Center, Beijing Tongren Hospital, Capital Medical University, Beijing Ophthalmology and Visual Sciences Key Laboratory, Beijing, China).

REFERENCES

1. Quigley HA, Broman AT. The number of people with glaucoma worldwide in 2010 and 2020. *Br J Ophthalmol* 2006; 90(3):262–267.
2. Bonomi L, Babighian S, Bonadimani M, et al. Correlation between glaucoma and vascular factors, and circumstances leading to the diagnosis of glaucoma. *Acta Ophthalmol Scand Suppl* 2000;78(232):34–35.
3. Leske MC, Wu SY, Hennis A, Honkanen R, Nemesure B, BESS Study Group. Risk factors for incident open-angle glaucoma: the Barbados Eye Studies. *Ophthalmology* 2008;115(1): 85–93.
4. Cherecheanu AP, Garhofer G, Schmidl D, Werkmeister R, Schmetterer L. Ocular perfusion pressure and ocular blood flow in glaucoma. *Curr Opin Pharmacol* 2013;13(1):36–42.
5. Ren R, Wang N, Zhang X, Tian G, Jonas JB. Cerebrospinal fluid pressure correlated with body mass index. *Graefes Arch Clin Exp Ophthalmol* 2012;250(3):445–446.
6. Abegao Pinto L, Willekens K, Van Keer K, et al. Ocular blood flow in glaucoma - the Leuven Eye Study. *Acta Ophthalmol* 2016;94(6):592–598.
7. Jonas JB. Role of cerebrospinal fluid pressure in the pathogenesis of glaucoma. *Acta Ophthalmol* 2011;89(6):505–514.
8. Morgan WH, Yu DY, Cooper RL, Alder VA, Cringle SJ, Constable IJ. The influence of cerebrospinal fluid pressure on the lamina cribrosa tissue pressure gradient. *Invest Ophthalmol Vis Sci* 1995;36(6):1163–1172.
9. Berdahl JP, Allingham RR, Johnson DH. Cerebrospinal fluid pressure is decreased in primary open-angle glaucoma. *Ophthalmology* 2008;115(5):763–768.
10. Hou R, Zhang Z, Yang D, et al. Intracranial pressure (ICP) and optic nerve subarachnoid space pressure (ONSP) correlation in the optic nerve chamber: the Beijing Intracranial and Intraocular Pressure (iCOP) study. *Brain Res* 2016;1635: 201–208.
11. Watanabe A, Kinouchi H, Horikoshi T, Uchida M, Ishigame K. Effect of intracranial pressure on the diameter of the optic nerve sheath. *J Neurosurg* 2008;109(2):255–258.
12. Geeraerts T, Newcombe VF, Coles JP, et al. Use of T2-weighted magnetic resonance imaging of the optic nerve sheath to detect raised intracranial pressure. *Crit Care* 2008; 12(5):R114.
13. Wang N, Xie X, Yang D, et al. Orbital cerebrospinal fluid space in glaucoma: the Beijing intracranial and intraocular pressure (iCOP) study. *Ophthalmology* 2012;119(10): 2065–2073.e2061.
14. Schneider CA, Rasband WS, Eliceiri KW. NIH Image to ImageJ: 25 years of image analysis. *Nat Methods* 2012;9(7): 671–675.
15. Soldatos T, Chatzimichail K, Papathanasiou M, Gouliamos A. Optic nerve sonography: a new window for the non-invasive evaluation of intracranial pressure in brain injury. *Emerg Med J* 2009;26(9):630–634.
16. Moretti R, Pizzi B, Cassini F, Vivaldi N. Reliability of optic nerve ultrasound for the evaluation of patients with

- spontaneous intracranial hemorrhage. *Neurocrit Care* 2009; 11(3):406–410.
17. Jonas JB, Wang N, Yang D, Ritch R, Panda-Jonas S. Facts and myths of cerebrospinal fluid pressure for the physiology of the eye. *Prog Retin Eye Res* 2015;46:67–83.
 18. Francois P, Lescanne E, Velut S. The dural sheath of the optic nerve: descriptive anatomy and surgical applications. *Adv Tech Stand Neurosurg* 2011;36:187–198.
 19. Helmke K, Hansen HC. Fundamentals of transorbital sonographic evaluation of optic nerve sheath expansion under intracranial hypertension. I. Experimental study. *Pediatr Radiol* 1996;26(10):701–705.
 20. Tayal VS, Neulander M, Norton HJ, Foster T, Saunders T, Blaivas M. Emergency department sonographic measurement of optic nerve sheath diameter to detect findings of increased intracranial pressure in adult head injury patients. *Ann Emerg Med* 2007;49(4):508–514.
 21. Beare NA, Kampondeni S, Glover SJ, et al. Detection of raised intracranial pressure by ultrasound measurement of optic nerve sheath diameter in African children. *Trop Med Int Health* 2008;13(11):1400–1404.
 22. Killer HE, Miller NR, Flammer J, et al. Cerebrospinal fluid exchange in the optic nerve in normal-tension glaucoma. *Br J Ophthalmol* 2012;96(4):544–548.
 23. Yablonski E, Rafalski K. Effect of time of administration of food supplement amino acids on protein utilization and the body composition of rats. *Vopr Pitan* 1979;12(5):17–21.
 24. Berdahl JP, Fautsch MP, Stinnett SS, Allingham RR. Intracranial pressure in primary open angle glaucoma, normal tension glaucoma, and ocular hypertension: a case-control study. *Invest Ophthalmol Vis Sci* 2008;49(12):5412–5418.
 25. Ren R, Jonas JB, Tian G, et al. Cerebrospinal fluid pressure in glaucoma: a prospective study. *Ophthalmology* 2010;117(2): 259–266.
 26. Bauerle J, Schuchardt F, Schroeder L, Egger K, Weigel M, Harloff A. Reproducibility and accuracy of optic nerve sheath diameter assessment using ultrasound compared to magnetic resonance imaging. *BMC Neurol* 2013;13:187.
 27. Jaggi GP, Miller NR, Flammer J, Weinreb RN, Remonda L, Killer HE. Optic nerve sheath diameter in normal-tension glaucoma patients. *Br J Ophthalmol* 2012;96(1):53–56.
 28. Abegao Pinto L, Vandewalle E, Pronk A, Stalmans I. Intraocular pressure correlates with optic nerve sheath diameter in patients with normal tension glaucoma. *Graefes Arch Clin Exp Ophthalmol* 2012;250(7):1075–1080.
 29. Copetti R, Cattarossi L. Optic nerve ultrasound: artifacts and real images. *Intensive Care Med* 2009;35(8):1488–1489. author reply 1490-1491.
 30. Raspanti M, Marchini M, Della Pasqua V, Strocchi R, Ruggeri A. Ultrastructure of the extracellular matrix of bovine dura mater, optic nerve sheath and sclera. *J Anat* 1992;181(Pt 2):181–187.
 31. Liu D, Kahn M. Measurement and relationship of subarachnoid pressure of the optic nerve to intracranial pressures in fresh cadavers. *Am J Ophthalmol* 1993;116(5):548–556.
 32. Spentzas T, Henricksen J, Patters AB, Chaum E. Correlation of intraocular pressure with intracranial pressure in children with severe head injuries. *Pediatr Crit Care Med* 2010;11(5): 593–598.
 33. Lirng JF, Fuh JL, Wu ZA, Lu SR, Wang SJ. Diameter of the superior ophthalmic vein in relation to intracranial pressure. *AJNR Am J Neuroradiol* 2003;24(4):700–703.